

Dysfunctional visual word form processing in progressive alexia

Stephen M. Wilson,^{1,2} Kindle Rising,¹ Matthew T. Stib,¹ Steven Z. Rapcsak^{1,2} and Pélégie M. Beeson^{1,2}

1 Department of Speech, Language and Hearing Sciences, University of Arizona, Tucson, AZ, USA

2 Department of Neurology, University of Arizona, Tucson, AZ, USA

Correspondence to: Stephen M. Wilson, Ph.D.
Department of Speech, Language and Hearing Sciences,
P.O. Box 210071, Tucson, AZ 85721, USA
E-mail: smwilson@u.arizona.edu.

Progressive alexia is an acquired reading deficit caused by degeneration of brain regions that are essential for written word processing. Functional imaging studies have shown that early processing of the visual word form depends on a hierarchical posterior-to-anterior processing stream in occipito-temporal cortex, whereby successive areas code increasingly larger and more complex perceptual attributes of the letter string. A region located in the left lateral occipito-temporal sulcus and adjacent fusiform gyrus shows maximal selectivity for words and has been dubbed the 'visual word form area'. We studied two patients with progressive alexia in order to determine whether their reading deficits were associated with structural and/or functional abnormalities in this visual word form system. Voxel-based morphometry showed left-lateralized occipito-temporal atrophy in both patients, very mild in one, but moderate to severe in the other. The two patients, along with 10 control subjects, were scanned with functional magnetic resonance imaging as they viewed rapidly presented words, false font strings, or a fixation crosshair. This paradigm was optimized to reliably map brain regions involved in orthographic processing in individual subjects. All 10 control subjects showed a posterior-to-anterior gradient of selectivity for words, and all 10 showed a functionally defined visual word form area in the left hemisphere that was activated for words relative to false font strings. In contrast, neither of the two patients with progressive alexia showed any evidence for a selectivity gradient or for word-specific activation of the visual word form area. The patient with mild atrophy showed normal responses to both words and false font strings in the posterior part of the visual word form system, but a failure to develop selectivity for words in the more anterior part of the system. In contrast, the patient with moderate to severe atrophy showed minimal activation of any part of the visual word form system for either words or false font strings. Our results suggest that progressive alexia is associated with a dysfunctional visual word form system, with or without substantial cortical atrophy. Furthermore, these findings demonstrate that functional MRI has the potential to reveal the neural bases of cognitive deficits in neurodegenerative patients at very early stages, in some cases before the development of extensive atrophy.

Keywords: progressive alexia; letter-by-letter reading; posterior cortical atrophy; logopenic primary progressive aphasia; visual word form system

Abbreviations: PCA = posterior cortical atrophy; VWFA = visual word form area

Introduction

Reading involves a complex mapping from a pattern of light on the retina to an abstract visual word form that is invariant for features such as size, location, case and font (Warrington and Shallice, 1980). Functional imaging studies suggest that this mapping depends on a hierarchical posterior-to-anterior gradient of processing in the ventral visual stream, with successive regions coding increasingly larger and more complex perceptual attributes of the letter string (Cohen *et al.*, 2003; Grainger and Whitney, 2004; Dehaene *et al.*, 2005; Vinckier *et al.*, 2007). Collectively, the cortical network of visual areas that support reading has been referred to as the visual word form system (Vinckier *et al.*, 2007). The earlier stages of processing are bilateral; primary visual cortex represents simple features such as oriented bars, and extrastriate visual areas extract local contours and then letter shapes. The culmination of this stream of processing is an abstract visual word form in a left-lateralized region located in the lateral occipito-temporal sulcus and/or adjacent fusiform gyrus (Binder and Mohr, 1992; Cohen *et al.*, 2000, 2002; Molko *et al.*, 2002; Clarke, 2003; Cohen *et al.*, 2003; Dehaene *et al.*, 2005; Vinckier *et al.*, 2007; Epelbaum *et al.*, 2008; Dehaene and Cohen, 2011). This region has been termed the 'visual word form area' (VWFA) (Cohen *et al.*, 2000). Although its functional specificity continues to be debated (Price and Devlin, 2003, 2011; Dehaene and Cohen, 2011; Vogel *et al.*, 2012), researchers concur that the VWFA plays an important role in reading.

Acquired reading deficits are traditionally divided into peripheral and central alexias. Peripheral alexias involve deficits in mapping visual inputs to visual word forms, whereas central alexias involve damage to orthographic representations or the mapping from orthography to phonological and/or semantic representations. When the visual word form system is damaged, words can no longer be recognized quickly and automatically. Reading is often possible to some extent, but it is characterized by a slow and effortful serial strategy referred to as letter-by-letter reading (Dejerine, 1892; Damasio and Damasio, 1983; Binder and Mohr, 1992; Beversdorf *et al.*, 1997; Cohen *et al.*, 2003; Leff *et al.*, 2006; Mani *et al.*, 2008; Pflugshaupt *et al.*, 2009). Although letter-by-letter reading is generally considered the most archetypal form of peripheral alexia, it should be noted that many patients with letter-by-letter reading also exhibit central orthographic processing deficits that may affect both reading and spelling (Behrmann *et al.*, 1998; Rapcsak and Beeson, 2004; Tsapkini and Rapp, 2010).

Acquired alexia due to neurodegenerative disease is termed 'progressive alexia'. Its onset is insidious and deficits become progressively worse over time (Mendez *et al.*, 2007). Acquired peripheral alexias are most commonly associated with the clinical neurodegenerative syndrome of posterior cortical atrophy (PCA) (Benson *et al.*, 1988), which usually reflects Alzheimer's pathology (Hof *et al.*, 1997; Tang-Wai *et al.*, 2004) though other aetiologies have been reported (Victoroff *et al.*, 1994). PCA is characterized by progressive deficits of visual and visuospatial functioning. Peripheral alexias are a prominent early symptom in most, if not all cases with PCA, often constituting the first clinical

manifestation of the disease (Benson *et al.*, 1988; McMonagle *et al.*, 2006). Patients with PCA have been reported to present with a variety of types of peripheral alexia including not only letter-by-letter reading, but also neglect alexia, attentional alexia, and alexia secondary to simultanagnosia (Cogan, 1985; De Renzi, 1986; Benson *et al.*, 1988; Freedman *et al.*, 1991; Freedman and Costa, 1992; Graff-Radford *et al.*, 1993; Ardila *et al.*, 1997; Beversdorf and Heilman, 1998; Mendez and Cherrier, 1998; Mendez *et al.*, 2002; Tang-Wai *et al.*, 2004; McMonagle *et al.*, 2006; Crutch and Warrington, 2007; Mendez *et al.*, 2007; Crutch and Warrington, 2009; Giovagnoli *et al.*, 2009; Catricalà *et al.*, 2011; Fragassi *et al.*, 2011). Alexia is typically out of proportion to any other language deficits that may occur, such as anomia or transcortical sensory aphasia (McMonagle *et al.*, 2006).

Although progressive peripheral alexia most frequently occurs in patients with PCA, it is also occasionally seen in cases of primary progressive aphasia. For instance, several patients with semantic dementia have been reported with letter-by-letter reading (Hodges *et al.*, 1992; Patterson and Hodges, 1992; Noble *et al.*, 2000). However, peripheral alexias are not common in primary progressive aphasia; more commonly seen are central alexias involving deficits in linking visual word forms to semantic or phonological representations (Hodges *et al.*, 1992; Patterson and Hodges, 1992; Mendez, 2002; Jefferies *et al.*, 2004; Brambati *et al.*, 2009; Wilson *et al.*, 2009; Henry *et al.*, 2012; Snowden *et al.*, 2012).

Relatively little is known about the neural substrates of progressive peripheral alexias with letter-by-letter reading. Most patients with clinically defined PCA have atrophy and/or hypometabolism of bilateral occipito-parietal and/or occipito-temporal cortex (Benson *et al.*, 1988; Graff-Radford *et al.*, 1993; Mendez *et al.*, 2002; Tang-Wei *et al.*, 2004; Whitwell *et al.*, 2007); however, imaging abnormalities are not apparent in all individuals (McMonagle *et al.*, 2006). Several cases have been reported in which alexia was the most prominent symptom and in which atrophy and/or hypometabolism were more pronounced in left than right posterior brain regions (Freedman *et al.*, 1991; Beversdorf and Heilman, 1998; Giovagnoli *et al.*, 2009; Fragassi *et al.*, 2011). There have also been suggestions that alexia in PCA may be related to ventral rather than dorsal pathology (Beversdorf and Heilman, 1998; Mendez and Cherrier, 1998). However, no structural or functional imaging studies have been carried out to identify which regions are specifically responsible for progressive alexia in PCA. Similarly, in primary progressive aphasia, although several studies have investigated the neural basis of central alexias (Brambati *et al.*, 2009; Wilson *et al.*, 2009; Henry *et al.*, 2012), it is not known which regions are implicated in the occasional patients with primary progressive aphasia whose alexia includes a peripheral component.

In this study, we investigated the structural and functional status of the visual word form system, including the VWFA, in two patients with progressive alexia and a profile of letter-by-letter reading. One patient was diagnosed with PCA and the other with logopenic variant primary progressive aphasia. We used a functional MRI paradigm that was optimized to detect the posterior-to-anterior gradient of selectivity for word forms, culminating in word-specific activity in the VWFA, in every individual

healthy control participant. We hypothesized that the visual word form system would be functionally abnormal in the two patients with progressive alexia, and by comparing the patients to healthy control subjects, we sought to characterize the nature of any functional abnormalities.

Previous functional imaging studies of patients with letter-by-letter reading due to stroke or surgical resection have revealed abnormal or absent neural activation when the VWFA is damaged or disconnected from its visual inputs (Cohen *et al.*, 2000, 2003, 2004; Henry *et al.*, 2005; Gaillard *et al.*, 2006; Epelbaum *et al.*, 2008; Ino *et al.*, 2008; Tsapkini *et al.*, 2011). All of these cases had frank structural damage to the visual word form system. In contrast, although our two patients had different degrees of atrophy in the visual word form system, no regions were completely destroyed, raising the question of whether functional abnormalities can be identified in such cases.

Materials and methods

Participants

Two individuals with progressive alexia participated in the study. Both were male, and aged 71 and 74, respectively, when they were scanned. Before scanning both patients completed a comprehensive battery of language, neuropsychological and reading evaluations, described below.

Control data for the functional imaging study were acquired from 10 healthy control participants who were primarily recruited from newspaper advertisements or flyers. These included five males and five females, with a mean age of 67 years (range: 50–77). In particular, there were four control males who were similar in age (72, 74, 75 and 77 years) to the two patients.

As control subjects for voxel-based morphometry, we used 9 of these 10 control subjects (the youngest, aged 50, was not used), plus an additional 13 age-matched control subjects who had been scanned on the same scanner for a different study, for a total of 22 control subjects. These included nine males and 13 females, with a mean age of 71 years (range: 63–77).

All participants gave written informed consent, and were compensated for taking part in the study. The study was approved by the University of Arizona Institutional Review Board.

Patient J: Case history and evaluations

Patient J was a left-handed male who was first seen in November 2010, at which time he was 70 years old. He had a masters degree in Fine Arts, had worked as an artist and art teacher, and continued to work part-time facilitating art classes. He described a 4 to 5-year history of progressive reading difficulties.

Because Patient J was left-handed, we used a standard clinical language mapping paradigm (picture naming) to determine whether his language areas were left-lateralized. This study revealed clear left lateralization for language processing (Supplementary Fig. 1). Because lateralization for reading tends to match lateralization for spoken language (Van der Haegen *et al.*, 2012), it is reasonable to assume that in Patient J, reading would probably also have been premorbidly left-lateralized.

Patient J's spoken language was largely intact (Table 1). In conversation, his output was fluent but characterized by mild anomia. In

formal testing, this was reflected in a score of 46 out of 60 on the Boston Naming Test. His comprehension of conversational speech was very good but there was a mild deficit on formal testing of single word comprehension; he made three semantic errors on spoken word-picture matching (PALPA 47); in each case, he chose semantically-related foils, e.g. he chose 'tiara' in response to 'crown'.

He did not show any significant cognitive, executive or memory deficits (Table 1). He performed poorly only on the Trail Making Test, which was presumably due to the fact that this test requires reading of letters and digits. He exhibited only mild visuospatial deficits; he performed well on copy and delayed copy of a modified Rey-Osterrieth figure (Fig. 1B and C) and well on face matching. However, he missed 3 of 10 items on the number location subtest from the Visual Object and Space Perception battery (VOSP) (Warrington and James, 1991), in which participants are asked to identify which of 16 digits in a square correspond to the location of a dot in an adjacent square.

Patient J was severely alexic (Table 2). Although he was highly educated, he was no longer reading at all in daily life. He was compensating through the use of books on tape and a computerized reading program. He had deficits at the single letter level, with errors on case matching, letter naming, and matching spoken-to-written letters (Table 2). He read single words extremely slowly with a letter-by-letter strategy, subvocally mouthing the individual letter names before eventually producing a response. His reading time increased as a function of word length (Fig. 2), a typical pattern in letter-by-letter readers. Because his single letter naming was error-prone, his letter-by-letter strategy was often not successful; overall, he read 70% of words and 50% of pseudowords correctly. His most frequent error types were visually similar words (46%, e.g. 'stale' for 'slate', 'bride' for 'bribe', 'circuit' for 'circuit'), probably reflecting his deficits at the single letter level. Other frequent error types were lack of any response (33%) and unrelated words (17%, e.g. 'step' for 'chef', 'huge' for 'laugh'). Paragraph reading was extremely slow. Patient J took 202 s to read the first two lines of a second grade level passage (18 words, 11.2 s per word), and he read only 11 of the 18 words correctly.

Patient J's written spelling was also impaired; he spelled 80% of regular real words, 60% of irregular real words, and 85% of pseudowords correctly. Direct copy of single words was good (96% letters correct), whereas case conversion was poor (58% correct), suggesting an allographic impairment, i.e. an impairment in mapping graphemes to letter shapes.

We evaluated Patient J again in June 2011, 7 months later. His anomia had progressed only slightly; he scored 42 out of 60 on the Boston Naming Test. In contrast, his reading was now dramatically worse. He read only 28% of words and 5% of pseudowords correctly. His most common error type was not to respond (73%, e.g. 'I don't know'), followed by visually similar words (22%, e.g. 'dump' for 'bump', 'comfort' for 'compact'). However, testing in the oral modality revealed strikingly spared orthographic knowledge. He was able to recognize 98% of words that were spelled out loud for him, and 90% of pseudowords.

Patient J's written spelling had further deteriorated; he now spelled only 55% of regular real words, 33% of irregular real words, and 65% of pseudowords correctly. However, he performed much better in oral testing, correctly spelling out loud 95% of regular words, 70% of irregular words, and 100% of pseudowords. The superior performance in oral spelling suggests a significant allographic impairment, whereas the pattern of surface agraphia in both modalities suggested mild damage to central orthographic representations.

In summary, Patient J presented with severe progressive alexia that was predominantly peripheral in nature, as evidenced by his very slow

Table 1 Language and neuropsychological measures in the two progressive alexic patients

| | Patient J | | Patient B |
|--|------------------------------------|--------------|--------------------------------------|
| | Nov 2010 | June 2011 | |
| Diagnosis | Progressive alexia and mild anomia | | Progressive alexia and logopenic PPA |
| Age | 70 | 71 | 73 |
| MMSE (/30) | 27 | 25 | 20 |
| Handedness | left-handed | | right-handed |
| Language measures | | | |
| Western Aphasia Battery Aphasia Quotient (/100) | 97.5 | — | 82.2 |
| WAB classification | Anomic | — | Anomic |
| Content (/10) | 10 | — | 9 |
| Fluency (/10) | 10 | — | 8 |
| Comprehension (/10) | 9.85 | — | 9.8 |
| Repetition (/10) | 10 | — | 7.4 |
| Naming (/10) | 8.9 | — | 6.9 |
| Boston naming test (/60) | 46 | 42 | 22 |
| Phonemic verbal fluency (generate words starting with d) | 10 | 10 | 7 |
| Semantic verbal fluency (generate animal names) | 9 | 7 | 11 |
| Pyramids and Palm Trees (pictures) | 52 | 51 | 45 |
| Pyramids and Palm Trees (written) | discontinued | too impaired | discontinued |
| Spoken word-picture match (PALPA 47, 5AFC, /40) | 37 | 34 | 40 |
| Arizona Phonological Battery (/100) | 94 | — | 45 |
| Cognitive/Executive/Memory | | | |
| Raven's Progressive Coloured Matrices (/36) | 31 | 31 | 21 |
| Trail Making Test A* | 81 s | — | 45 s |
| Trail Making Test B* | > 300 s | — | discontinued |
| Digits forward | 8+ | 7 | 5 |
| Digits backwards | 5 | 3 | — |
| Visuospatial tests** | | | |
| Modified Rey-Osterrieth copy (/17) | — | 13 | 13 |
| Modified Rey-Osterrieth delayed copy (/17) | — | 13 | 6 |
| Modified Rey-Osterrieth recognition (yes/no) | — | yes | yes |
| Number location (VOSP) (/10) | — | 7 | 8 |
| Face matching (CATS) (/12) | — | 11 | 11 |

MMSE = Mini-Mental State Examination (Folstein *et al.*, 1975); WAB = Western Aphasia Battery (Kertesz, 1982); PALPA = Psycholinguistic Assessments of Language Processing in Aphasia (Kay *et al.*, 1992); VOSP = number location subtest from the Visual Object and Space Perception battery (Warrington and James, 1991); CATS = face matching subtest from the Comprehensive Affect Testing System (Froming *et al.*, 2006).

Boston Naming Test (Kaplan *et al.*, 1983); Pyramids and Palm Trees (Howard and Patterson, 1992); Arizona Phonological Battery (Rapcsak *et al.*, 2009); Raven's Progressive Colored Matrices (Raven *et al.*, 1990); modified Rey-Osterrieth figure copy and recall (Possin *et al.*, 2011).

— = not tested.

5AFC = 5-alternative forced choice.

* Performance on the Trail Making Test was presumably compromised by reading deficits. Normal performance on Trails A in this age range is 40 ± 14 s (education > 12 years, as for Patient J) or 42 ± 15 s (education ≤ 12 years, as for Patient B). Normal performance on Trails B is 86 ± 24 s (education > 12 years) or 110 ± 35 s (education ≤ 12 years) (Tombaugh, 2004).

** Visuospatial tests were performed several months later than the other tests.

and error-prone letter-by-letter reading. In addition, he showed a significant allographic impairment and mild damage to central orthographic representations. Patient J met criteria for the clinical syndrome of PCA (Tang-Wei *et al.*, 2004). We scanned him in June 2011, shortly after this second evaluation.

Patient B: Case history and evaluation

Patient B was a right-handed male who was first seen in June 2010, at which time he was 73-years-old. He had an eighth grade education, had worked as a construction foreman, and was the owner of a

company involved in the mining industry. He described an ~18-month history of difficulty expressing himself, which he first noticed as a difficulty in telling jokes, and progressive reading difficulties over the same period.

His spoken language was characterized by prominent anomia, circumlocutions, and retracings, and mild comprehension difficulties were evident in conversation. Language testing resulted in a clinical diagnosis of logopenic progressive aphasia (Gorno-Tempini *et al.*, 2011), supported by anomia in spontaneous speech and confrontation naming, impaired repetition, and preserved single word comprehension, motor speech, and grammatical function (Table 1).

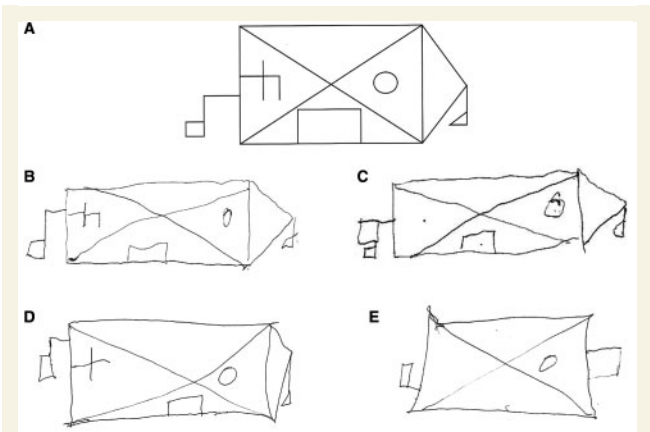


Figure 1 Preserved figure copy and delayed copy in the two patients with progressive alexia. (A) The modified Rey-Osterrieth figure (Possin *et al.*, 2011). (B) Patient J's copy of the figure. (C) Patient J's delayed copy of the figure after 10 min. (D) Patient B's copy of the figure. (E) Patient B's delayed copy of the figure after 10 min.

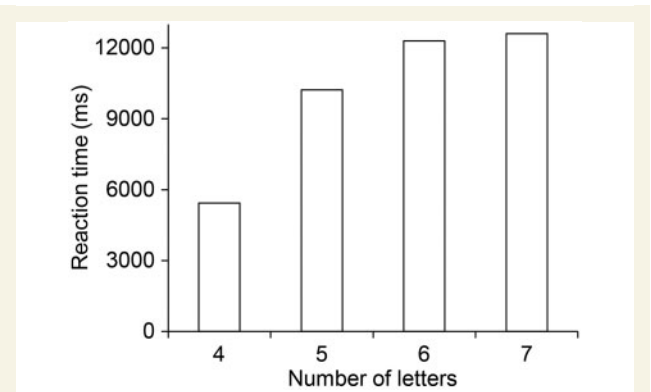


Figure 2 Reading time increased as a function of word length in Patient J, a pattern that is characteristic of letter-by-letter reading.

Table 2 Orthographic, reading, writing and spelling measures in the two progressive alexic patients

| | Patient J | | Patient B |
|--|--------------|--------------|-----------|
| | Nov 2010 | June 2011 | |
| Single letter tasks | | | |
| Mirror reversal (PALPA 18, 2AFC, /36) | 35 | 35 | 32 |
| Case matching (PALPA 19/20, 2AFC, /52) | 47 | 46 | 37 |
| Letter naming (PALPA 22, /26) | 20 | 17 | — |
| Spoken letter-written letter match (PALPA 23, 4AFC, /26) | 23 | 22 | 21 |
| Reading | | | |
| Lexical decision, illicit foils (PALPA 24, 2AFC, /60) | 51 | 49 | 54 |
| Lexical decision, plausible foils (PALPA 25, 2AFC, /60) | discontinued | too impaired | 36 |
| Orthographic choice (2AFC, /40) | 22 | too impaired | 30 |
| Oral reading of regular words (ABRS) (/40) | 31 | 13 | 7 |
| Oral reading of irregular words (ABRS) (/40) | 25 | 9 | 9 |
| Oral reading of pseudowords (ABRS) (/20) | 10 | 1 | 0 |
| Oral 'reading' of regular words spelled out loud (/40) | — | 39 | — |
| Oral 'reading' of irregular words spelled out loud (/40) | — | 39 | — |
| Oral 'reading' of pseudowords spelled out loud (/20) | — | 18 | — |
| Written word-picture match (PALPA 48, 5AFC, /40) | 37 | 23 | 29 |
| Writing and spelling | | | |
| Direct copy of single words (% letters correct) | 96% | 87% | 90% |
| Case conversion (/52) | 30 | 30 | 37 |
| Written spelling of regular words (ABRS) (/40) | 32 | 22 | 12 |
| Written spelling of irregular words (ABRS) (/40) | 24 | 13 | 5 |
| Written spelling of pseudowords (ABRS) (/20) | 17 | 13 | 2 |
| Oral spelling of regular words (ABRS) (/40) | — | 38 | — |
| Oral spelling of irregular words (ABRS) (/40) | — | 28 | — |
| Oral spelling of pseudowords (ABRS) (/20) | — | 20 | — |

PALPA = Psycholinguistic Assessments of Language Processing in Aphasia (Kay *et al.*, 1992); ABRS = Arizona Battery for Reading and Spelling (Henry *et al.*, 2007; Rapcsak *et al.*, 2009; Beeson *et al.*, 2010).
 Control subjects make only occasional sporadic errors and are at ceiling for all measures (Beeson *et al.*, 2010).
 — = not tested.
 nAFC = *n*-alternative forced choice.

Mr. B showed moderate cognitive deficits, as evidenced by poor performance on Raven's progressive coloured matrices (Table 1). He performed poorly on the Trail Making Test but, as noted above, this test requires reading of letters and digits. He exhibited only mild visuo-spatial deficits; he performed well on copy and moderately well on delayed copy of a modified Rey-Osterrieth figure (Fig. 1D and E). He missed 2 of the 10 items on the number location subtest from the Visual Object and Space Perception battery, but he did well on face matching.

Patient B reportedly had never been much of a reader, but he had read the Bible and trade magazines. He described reading less and less as he had found it becoming increasingly difficult. Patient B's reading was severely impaired (Table 2), with deficits at the single letter level evident in errors on discrimination of mirror-reversed letters, case matching, and case conversion. He employed a laborious letter-by-letter reading strategy that was often unsuccessful due to his difficulties in the identification of individual letters. The following examples are typical of his attempts to read single words:

- (1) [target: reach] B R E A T H, beneath, bearth, I dunno, that's not it
- (2) [target: shove] S H O P E sharp, no
- (3) [target: choir] cough, C O U M D, cough, that don't sound right, cough, C O U, no that's not C O, C H O I R, cough, no, it's C O U something, C H O I R.

Overall, single words were read correctly just 20% of the time, and no pseudowords were read correctly. The most common error types were unrelated words (30%, e.g. 'touch' for 'doubt') and visually similar words (22%, e.g. 'change' for 'charge'). Too few of his responses were correct to permit the calculation of reaction time.

Patient B was generally unable to pronounce words that were spelled out loud for him, but this was not formally tested (note that the phonological short-term memory deficits of logopenic primary progressive aphasia would make this challenging even if orthographic representations were intact). Written spelling was also very poor for both words and pseudowords.

In sum, patient B showed severe progressive alexia with a significant peripheral component, as evidenced by his slow and error-prone letter-by-letter reading. His spelling impairment for both words and pseudowords indicated damage to lexical-semantic and sublexical spelling mechanisms. In addition, Patient B demonstrated prominent spoken language deficits, meeting diagnostic criteria for logopenic primary progressive aphasia (Gorno-Tempini *et al.*, 2011). We scanned Patient B ~1 year after we first saw him, in June 2011.

Functional magnetic resonance imaging experimental design

The aim of our functional imaging study was to determine whether the visual word form system was functionally normal in the two patients with progressive alexia, therefore it was important to optimize our paradigm such that the functional organization of the visual word form system could be robustly mapped in each individual healthy control participant. Otherwise a seemingly abnormal pattern in the patients might just reflect interindividual variability, and would be difficult to interpret. Pilot studies suggested that four design features were important to reliably map the visual word form system: (i) a block design to maximize signal to noise; (ii) a control condition closely matched for low-level visual features; (iii) a rapid presentation rate; and (iv) an attentionally demanding non-linguistic task. It is likely that these last two features minimize semantic processing and other higher

level processing of the stimuli, and thus are more effective in revealing lower level processes, which are more consistent across subjects than higher level processes. Rapid presentation rates and attentionally demanding tasks have been used in previous studies aimed at mapping response selectivity in occipito-temporal cortex (Vinckier *et al.*, 2007). We used false font strings rather than non-word orthographic strings as the control condition, because activation levels for non-word strings depend heavily on the orthographic plausibility of the non-word strings. Implausible non-words behave like false fonts, whereas plausible non-words produce similar levels of activity to real words (Vinckier *et al.*, 2007).

Participants were scanned with functional MRI as they viewed blocks of rapidly presented words, false font strings, or a fixation crosshair, while performing an attentionally demanding non-linguistic task. Each block was 20 s long, and in each run there were six repetitions of each of the three conditions, presented in pseudorandom order, for a total run length of 6 min, plus 8 s to acquire four additional volumes that were discarded. Participants completed two runs each, except for one control participant, who completed only one run.

The stimulus words were nouns and adjectives selected from the Medical Research Council database (Coltheart, 1981). They were all six letters long and medium frequency, with Kucera-Francis frequencies ranging from 10 to 110. Proper names and some emotive words were excluded. Words were shown in Times New Roman font, all capitals, centred on a fixation cross. Words were presented in white on a grey background for 100 ms, then a white fixation cross was displayed for 200 ms, then the next word was presented. There were 67 words in each 20-s block.

The false font stimuli were created using letters from alphabetic orthographies other than English. These stimuli were presented with the same timing and visual parameters as the words.

The task was to detect occasional words or false font strings presented in red instead of white, and then press a button on a response pad as quickly as possible. These catch trials were presented pseudorandomly in four of the six word blocks, and four of the six false font blocks.

Participants were familiarized with the stimuli and practiced the task, before being placed in the scanner.

Neuroimaging protocol

Participants were scanned as they lay supine in a General Electric 3 T HD Signa Excite scanner at the University of Arizona Medical Centre. They viewed the stimuli through magnetic resonance-compatible goggles (Resonance Technology, Inc), and wore padded headphones and earplugs to attenuate scanner noise.

For anatomical reference and registration, a T₁-weighted 3D spoiled gradient recalled inversion recovery sequence was acquired with the following parameters: 160 sagittal slices; slice thickness = 1 mm; field of view = 256 × 256 mm; matrix = 256 × 256 mm; repetition time = 7.5 ms; echo time = 3.0 ms; inversion time = 500 ms; flip angle = 15°.

For the functional imaging paradigm, 184 blood oxygen level-dependent T₂*-weighted volumes were acquired using a single-shot spiral pulse sequence (Glover and Law, 2001) with the following parameters: 30 anterior commissure/posterior commissure-aligned axial slices in sequential order; slice thickness = 4 mm with no gap; field of view = 240 × 240 mm; matrix = 64 × 64; repetition time = 2000 ms; echo time = 30 ms; flip angle = 90°.

Visual stimuli were presented with PsychToolbox 3.0.8 (Brainard, 1997; Pelli, 1997) running under MATLAB 7.11 (Mathworks) on a Windows PC.

Voxel-based morphometry

The T₁-weighted structural images were bias-corrected, segmented into grey matter, white matter and CSF, and normalized to MNI space using the unified segmentation algorithm in SPM (version SPM5; <http://www.fil.ion.ucl.ac.uk/spm>; Ashburner and Friston, 2005). Grey matter and white matter probability maps were scaled by Jacobians, smoothed with a Gaussian kernel of 10 mm full-width half-maximum, then summed together to obtain a map of brain parenchyma (Wilson *et al.*, 2010). Each of the two patients was compared to the 22 control subjects, with age, sex and total intracranial volume included as covariates. Statistical maps were thresholded at voxelwise $P < 0.005$, with a minimum cluster size of 1500 mm³.

Functional magnetic resonance imaging data analysis

The functional imaging data were preprocessed with AFNI (version 2011-06-22; <http://afni.nimh.nih.gov/afni>; Cox, 1996). The data were corrected for slice timing differences, realigned to account for head movement, smoothed with a Gaussian kernel of 4 mm full-width half-maximum, high pass filtered (cut-off = 0.006 Hz) and detrended (Legendre polynomials of order up to and including two). A general linear model was fit at each voxel using the 'fmrilm' procedure from FMRISTAT (version 2006-06-02; <http://www.math.mcgill.ca/keith/fmrstat>; Worsley *et al.*, 2002), modelling temporal autocorrelation as an autoregressive process of degree one.

The design matrix contained one explanatory variable for word blocks and one for false font blocks, each convolved with a canonical haemodynamic reference function modelled as a difference of two gamma functions. Six head motion parameters, slow drift parameters, and the global whole-brain signal were included as covariates of no interest. Each subject's two runs were combined with a fixed effects model using the 'multistat' procedure from FMRISTAT.

Functional images were initially coregistered to structural images using SPM5, then manually realigned for greater accuracy. Anatomical images were transformed to MNI space with SPM5, and this transformation was then applied to the statistical images.

To identify the VWFA in each individual subject, we contrasted words to false font strings at voxelwise $P < 0.05$, masked by the contrast of words to fixation at $P < 0.0001$ (*cf.* Glezer *et al.*, 2009). We considered only clusters with a centre of mass within 15 mm of the published VWFA coordinates of (−42, −57, −15) (Cohen *et al.*, 2002).

Whole brain random effects group analyses were carried out after applying a second smoothing kernel (6 mm full-width half-maximum) to the individual effect size images. To identify the VWFA in the 10 control subjects, we contrasted words to false font strings. This analysis was thresholded at voxel-wise $P < 0.005$ and corrected for multiple comparisons at $P < 0.05$ based on cluster extent (Worsley *et al.*, 1996). To identify regions where the two patients showed less activation than the 10 control subjects, we compared the contrast of words to false font strings between the patients and control subjects using a two-sample *t*-test with pooled variance. This analysis was thresholded at voxelwise $P < 0.005$, then corrected for multiple comparisons (Friston *et al.*, 1997) based on the extent of the closest cluster to the published coordinates of the VWFA, which was the region hypothesized to show reduced activation in patients.

Previous studies have demonstrated a posterior-to-anterior gradient of visual word form processing in the ventral visual stream, with successively anterior regions increasingly selective for words (Vinckier *et al.*, 2007). To identify this selectivity gradient in each individual

subject, we created images showing the signal for false font strings as a proportion of the signal for words, in regions that were active for words versus fixation at $P < 0.0001$. We also plotted the mean signal for words and false font strings in occipito-temporal cortex in each hemisphere as a function of *y* coordinate (i.e. posterior-to-anterior), by averaging across a region of interest defined by the control group activation for words versus rest thresholded as described above (voxelwise $P < 0.005$ and corrected for multiple comparisons at $P < 0.05$).

Results

Voxel-based morphometry

Voxel-based morphometry showed that Patient J had very mild atrophy of the left posterior inferior temporal gyrus, and widening of the left sylvian fissure (Fig. 3A, Table 3).

Patient B had much more extensive atrophy of the left inferior and middle temporal gyri, the left fusiform gyrus, the white matter underlying these regions, and a smaller region of the right posterior inferior temporal gyrus (Fig. 3B, Table 3).

Behavioural data collected during functional magnetic resonance imaging

Control subjects responded to 90.5% ± 15.8% (SD) of the catch trials (occasional words or false font strings coloured red instead of white). Patient J responded to 87.5% of the catch trials, and Patient B responded to 100% of the catch trials. Most participants also made occasional false positive responses.

Functional magnetic resonance imaging

All 10 control subjects showed a VWFA that responded more to words than false font strings according to our criteria (Fig. 4A–C, Table 4). For the more basic contrasts of words versus fixation and false font strings versus fixation, all control subjects showed bilateral occipito-temporal activation (Fig. 4A–C).

Unlike the control subjects, neither of the two patients with progressive alexia showed a VWFA according to our criteria (Fig. 4D and E, Table 4). For the more basic contrasts relative to fixation, the two patients differed from one another. Patient J showed typical robust bilateral occipito-temporal activation for both of these contrasts (Fig. 4D). Patient B showed much weaker activation for these contrasts, with more activity in the right than the left hemisphere (Fig. 4E).

We next checked whether loosening our criteria for the VWFA (i.e. words versus false font strings $P < 0.05$, words versus fixation $P < 0.0001$, within 15 mm of published coordinates) would reveal any evidence for a VWFA in either patient. For Patient J, there were two single voxels meeting the voxel-wise criteria in left occipito-temporal cortex; however, the closest to the VWFA was 27 mm away at (−52, −82, −14). In right occipito-temporal cortex there was a cluster of 39 voxels with centre of mass (41, −57, 2), which is 17 mm from the right hemisphere homologue of the VWFA. We then examined the contrast of words versus false fonts without the mask of words versus rest, and observed a cluster of 44 voxels with centre of mass (−60, −56, −11), which is

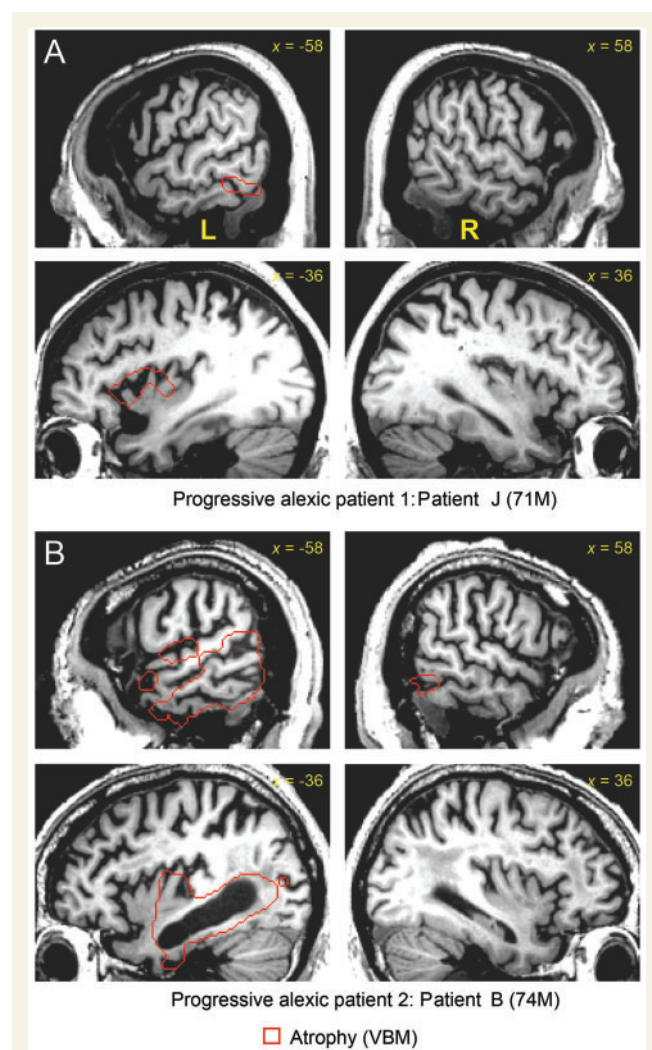


Figure 3 Structural images of the two progressive alexic patients. Regions of tissue loss as revealed by voxel-based morphometry (voxel-wise $P < 0.005$, minimum cluster extent = 1500 mm^3) are shown with red outlines (white in printed version). (A) Patient J showed mild atrophy of the left posterior inferior temporal gyrus. (B) Patient B showed much more extensive atrophy of left temporal cortex. VBM = voxel-based morphometry.

18 mm from the VWFA. However, activation at that location was slightly negative for all words relative to rest, suggesting that the cluster arose due to a deactivation for false font strings. A failure to activate for words relative to rest is inconsistent with the response properties of the VWFA. For Patient B, there were no voxels meeting the voxel-wise criteria in left occipito-temporal cortex. In right occipito-temporal cortex there were a few scattered voxels meeting the voxel-wise criteria, but none were close to the right homologue of the VWFA; the closest was located at $(-40, -72, -2)$, which is 20 mm from the right hemisphere homologue of the VWFA. We then examined the contrast of words versus false fonts without the mask of words versus rest, and observed a small cluster of nine voxels with centre of mass $(-50, -43, -10)$, which is 17 mm from the VWFA. But activation

Table 3 Voxel based morphometry showing tissue loss in the two progressive alexic patients

| Brain region | MNI coordinates | | | Max t | Extent (mm ³) |
|---|-----------------|-----|-----|-------|---------------------------|
| | x | y | z | | |
| Patient J | | | | | |
| Left posterior inferior temporal gyrus | −56 | −55 | −16 | 4.75 | 1680 |
| Left sylvian fissure (widening) | −40 | 2 | 2 | 4.72 | 5880 |
| Patient B | | | | | |
| Left inferior and middle temporal gyri and fusiform gyrus | −44 | −40 | −9 | 9.67 | 80032 |
| Right posterior inferior temporal gyrus | 57 | −58 | −15 | 5.20 | 2368 |

Thresholded at voxel-wise $P < 0.005$, cluster extent $> 1500 \text{ mm}^3$. Extent is the size of the region in which there was significant tissue loss (voxel-wise $P < 0.005$) compared with control subjects.

at that location was slightly negative for all words relative to rest, inconsistent with the response properties of the VWFA. In summary, neither patient showed any activation resembling a typical VWFA, even when the criteria were relaxed.

We next performed a whole-brain random effects analysis contrasting words to false font strings in the 10 control subjects. The VWFA was the only region activated (centre of mass: $-43, -50, -18$; extent = 6312 mm^3 ; corrected $P < 0.001$) (Fig. 5A). We then directly compared the two patients to the 10 control subjects. The patients showed significantly less activation than control subjects in the VWFA (centre of mass: $-39, -45, -19$; extent = 1000 mm^3 ; corrected $P = 0.034$) (Fig. 5B). This was the largest cluster observed, and no other clusters reached significance.

To reveal the anticipated posterior–anterior gradient of selectivity for words, we plotted the signal to false font strings as a proportion of the signal to words, in regions that were active for words versus fixation (Fig. 6). We found evidence for this gradient in each of the 10 control subjects (Fig. 6A–J). There was some individual variability, for instance, Control Subject 4 (who was left-handed) showed a typical gradient in the left hemisphere, but an even stronger gradient in the right hemisphere; Control Subject 5 showed rather weak activity for both conditions relative to rest; and Control Subject 9 showed an additional word-selective region more posteriorly. However, despite this variability, left hemisphere posterior–anterior gradients were evident in all control subjects.

In contrast, neither of the two patients with progressive alexia exhibited a posterior–anterior gradient of selectivity for words (Fig. 6K and L). Both patients had small regions in the right hemisphere that were selective for words at $P < 0.05$, but in both cases these were considerably dorsal to the right hemisphere homologue of the VWFA (Fig. 6K and L).

We also plotted the mean signal for words and false font strings in occipito-temporal cortex in each hemisphere as a function of

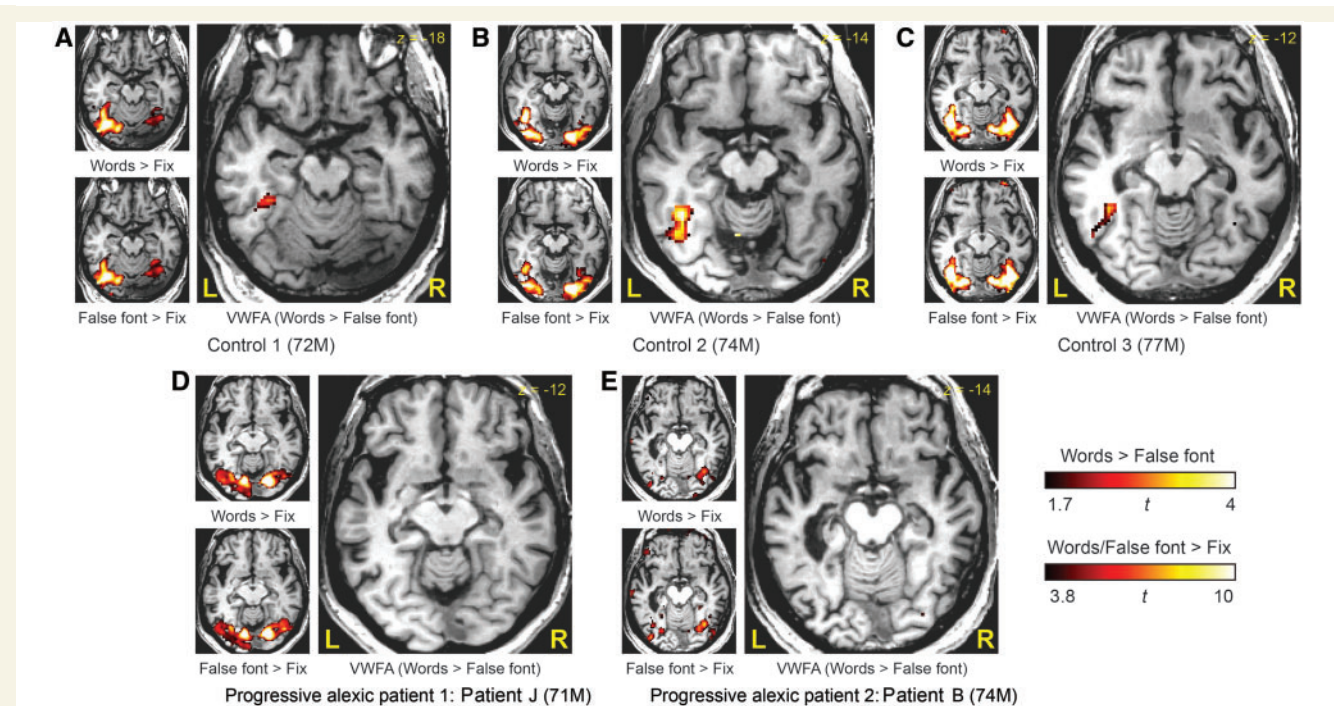


Figure 4 Functional identification of the visual word form area. (A, B and C) In three typical control subjects, viewing words or false font strings relative to fixation activated bilateral occipital and posterior temporal regions (voxel-wise $P < 0.0001$). The contrast of words versus false font strings (voxel-wise $P < 0.05$) masked by the contrast of words versus rest (voxel-wise $P < 0.0001$) revealed the VWFA in each of the 10 control participants. (D) Patient J showed typical bilateral occipito-temporal activation for words or false font strings relative to fixation, however there were no regions activated for words versus false font strings. (E) Patient B showed weak right-lateralized activation for words or false font strings relative to fixation, and no regions activated for words versus false font strings.

Table 4 Localization of VWFA with functional MRI

| Subject | MNI coordinates of VWFA | | | Distance (mm) | Max t | Extent (mm ³) |
|------------|-------------------------|------|-----|------------------|---------|------------------------------|
| | x | y | z | | | |
| Control 1 | −37 | −45 | −23 | 15 | 2.89 | 928 |
| Control 2 | −44 | −54 | −16 | 4 | 5.25 | 3432 |
| Control 3 | −45 | −56 | −9 | 6 | 4.05 | 2704 |
| Control 4 | −35 | −45 | −20 | 15 | 2.90 | 616 |
| Control 5 | −45 | −56 | −15 | 3 | 2.34 | 96 |
| Control 6 | −41 | −60 | −12 | 4 | 3.72 | 4328 |
| Control 7 | −51 | −51 | −14 | 11 | 5.45 | 3416 |
| Control 8 | −42 | −52 | −13 | 6 | 5.99 | 3184 |
| Control 9 | −43 | −52 | −12 | 6 | 6.56 | N/A* |
| Control 10 | −43 | −52 | −14 | 5 | 4.63 | N/A* |
| Patient J | | None | | | | |
| Patient B | | None | | | | |

Distance is the distance from the VWFA coordinates of (−42, −57, −15) reported by Cohen *et al.* (2002).
*Clusters for these subjects were contiguous with other clusters outside the VWFA, so cluster extent could not be determined. The t threshold was raised until the clusters separated to determine the centre of mass of the VWFA cluster.

y coordinate (i.e. posterior-to-anterior) (Fig. 6). This analysis highlighted a notable difference between the two patients. Patient J showed normal responses to both words and false font strings in posterior occipito-temporal cortex, but unlike control subjects, he showed no emergence of selectivity for words more anteriorly.

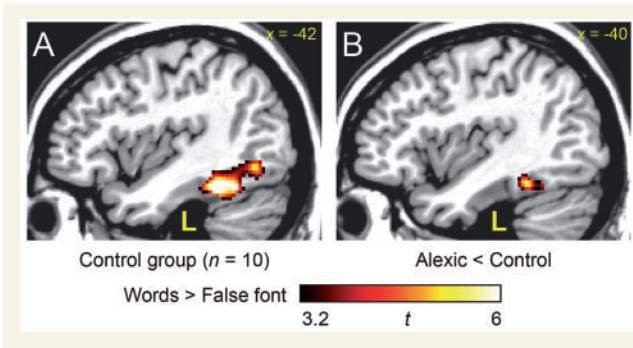


Figure 5 The visual word form area in control subjects and patients. (A) In the control group, the contrast of words versus false font strings (voxel-wise $P < 0.005$, corrected for multiple comparisons at $P < 0.05$) revealed the visual word form area. (B) Activation for this contrast was reduced in the patients relative to the control subjects (voxel-wise $P < 0.005$, corrected for multiple comparisons at $P < 0.05$).

In fact, he showed somewhat less activity for words than false font strings in the vicinity of the VWFA. In contrast, Patient B showed minimal activation for either words or false font strings in any part of occipito-temporal cortex. In this respect, Patient B differed from Patient J and the control subjects, all of whom showed robust responses for both words and false font strings relative to rest.

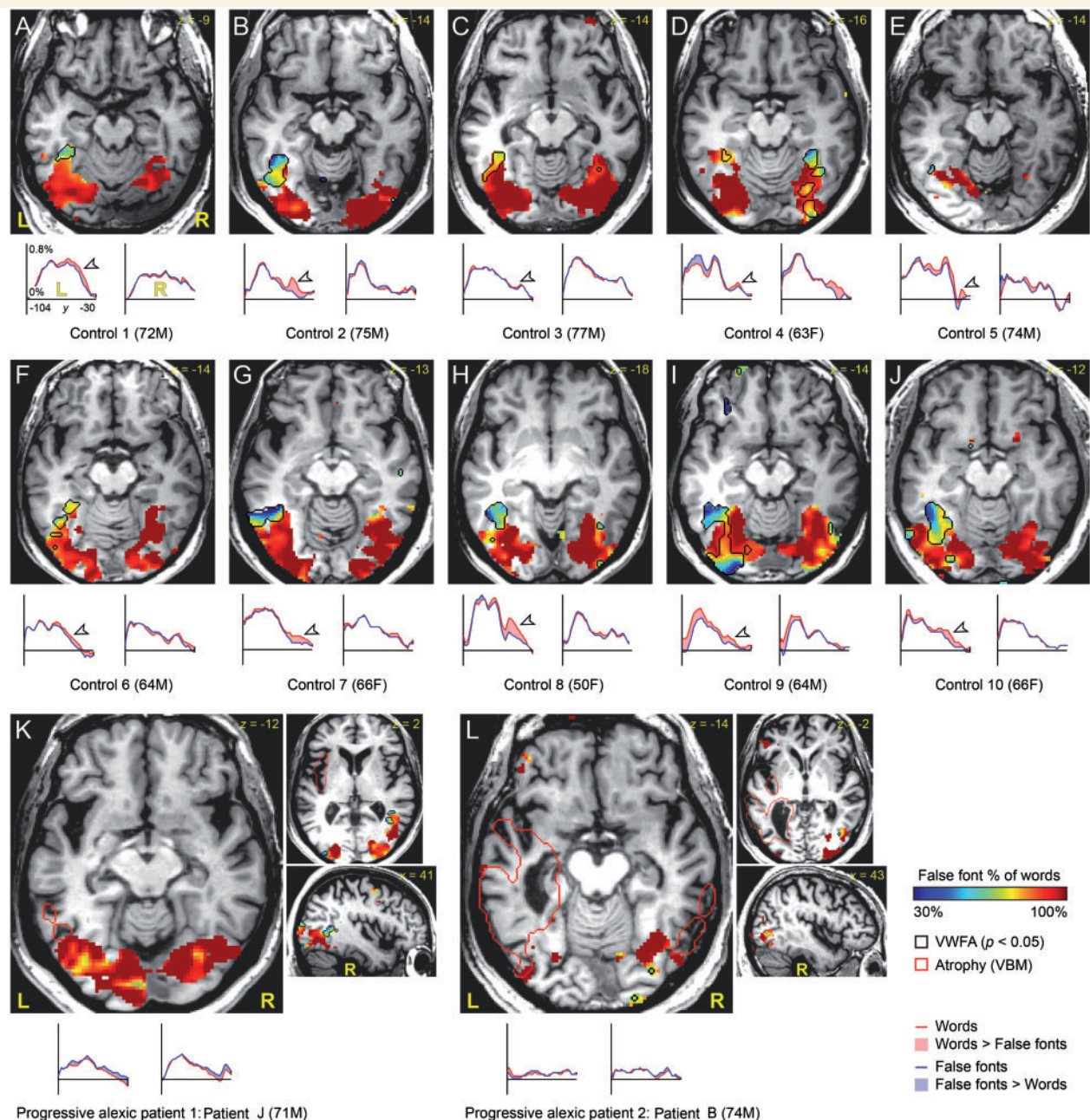


Figure 6 The typical anterior-posterior gradient of selectivity for words in occipito-temporal cortex was abnormal in the two patients with progressive alexia. (A–J) In all control subjects, posterior occipito-temporal cortex responded as much for false font strings as for words, whereas more anterior regions showed greater responses to words than false font strings. This pattern was also apparent (arrowheads) when plotting mean occipito-temporal responses in each hemisphere to words and false font strings as a function of y coordinate, as shown in the line graphs below each image. (K and L) This selectivity gradient for words was not apparent in either of the two progressive alexic patients. Additional slices are shown to demonstrate that both patients showed small regions that were selectively responsive to words more dorsally in the right hemisphere. The black outlines show regions that responded more to words than false font strings (voxel-wise $P < 0.05$) and more to words than fixation (voxel-wise $P < 0.0001$). The red outlines show regions in the two patients that VBM showed to be atrophic (voxel-wise $P < 0.005$, minimum cluster extent = 1500 mm³). F = female; M = male.

Discussion

The goal of this study was to investigate the structural and functional status of the visual word form system, including the VWFA, in two patients with progressive alexia. Structural imaging showed

left-lateralized occipito-temporal atrophy in both patients, mild in one (Patient J) but moderate to severe in the other (Patient B). Functional imaging in control subjects revealed a posterior-to-anterior gradient of selectivity for words, and all 10 showed a functionally defined VWFA that was activated for words relative

to false font strings. In contrast, neither of the two patients showed any evidence for a selectivity gradient or for word-specific activation of the VWFA. These findings support our hypothesis that the visual word form system would be functionally abnormal in progressive alexia.

Patient J showed normal bilateral occipito-temporal responses for words relative to rest and false fonts relative to rest, whereas Patient B showed reduced activation even in these basic contrasts. This may be related to the degree of occipito-temporal atrophy, which was much greater in Patient B. Because Patient B showed abnormal activity even in basic contrasts in regions posterior to the VWFA, it seems clear that early processing stages in the visual word form system were implicated in his reading deficit, consistent with the fact that his deficits extended even to the single letter level. Patient J, in contrast, did not lack activation of regions posterior to the VWFA. Rather, he lacked any emergence of selectivity for words. Whereas the dysfunction of his visual word form system was more subtle than that of Patient B, regions posterior to the VWFA may likewise be implicated as Patient J also had deficits at the single letter level. Although our data suggest that functional abnormalities arise posterior to the VWFA in both patients, it should be emphasized that neither patient had severe visual perceptual deficits, and object recognition was intact. Both patients' deficits were quite specific for reading.

A crucial methodological aspect of our study was the optimization of a paradigm that would reliably activate the VWFA in every individual normal control subject. Otherwise, failure to detect the VWFA in the patients with progressive alexia might simply reflect a lack of statistical power. We used a block design with false font control stimuli, rapid presentation, and an attentionally demanding task in order to maximize power, minimize visual confounds, and minimize higher level semantic processing. This design was quite similar to that used by Vinckier *et al.* (2007). Our pilot testing showed that with slower presentation rates, there was considerable interindividual variability presumably related to higher level processing, and words did not necessarily activate the VWFA more than visually matched non-word stimuli such as false fonts or consonant strings. Others have made similar observations (Tagamets *et al.*, 2000; Cohen *et al.*, 2003). Our optimized paradigm was successful in identifying the VWFA and mapping the posterior-to-anterior gradient of selectivity for words in all 10 of our healthy control participants. Because of this consistency, we can be confident that the abnormal functionality of the visual word form system in the two patients is unlikely to reflect normal individual variability. A direct comparison between the two patients and the 10 control subjects provided further support for this conclusion.

Previous functional imaging studies of the VWFA and earlier visual processing areas in patients have shown that the VWFA does not show typical activation for word reading or selectivity for words when it is damaged or disconnected from its inputs [Cohen *et al.*, 2003, 2004 (Patient F), Henry *et al.*, 2005; Gaillard *et al.*, 2006; Epelbaum *et al.*, 2008]. Sometimes rather precise disconnections have been demonstrated. For instance, damage to the white matter in the splenium of the corpus callosum or its continuation in the forceps major disconnects the VWFA from right hemisphere visual processing areas, resulting in

hemialexia in the left visual field; in these patients, the VWFA is not activated by words presented in the left visual field [Cohen *et al.*, 2000, 2003 (Patient D)]. Damage to earlier visual processing regions in the left hemisphere does not result in alexia if right hemisphere regions are intact and interhemispheric connectivity is preserved; in these cases, the VWFA is activated normally [Cohen *et al.*, 2003 (Patient M)]. The importance of the VWFA at the anterior endpoint of the visual word form processing stream has been highlighted in particular by two studies. Ino *et al.* (2008) reported a patient who became alexic after haemorrhage in the vicinity of the VFWA. The patient lacked functional activity in the VWFA, but 6 weeks later his reading had recovered, and the VWFA showed functional activity for reading again. Tsapkini *et al.* (2011) showed that VWFA-like activation was displaced posteriorly in a patient with a left fusiform resection, resulting in a limited reading deficit. Our two cases differ from all of these previous cases of acquired alexia in that the VWFA was neither completely destroyed nor deafferented by a frank structural lesion. However, our results converge with findings of abnormal functionality in the visual word form system in children and adults with developmental dyslexia, in whom there may be structural abnormalities but there are no frank lesions (Salmelin *et al.*, 1996; Rumsey *et al.*, 1997; McCrory *et al.*, 2005; van der Mark *et al.*, 2009, 2011).

Our two patients with progressive alexia met criteria for different clinical syndromes. Patient J likely represents an early case of PCA, whereas Patient B met diagnostic criteria for logopenic primary progressive aphasia. Here we consider our findings for each patient in the context of their broader clinical syndrome.

Patient J met clinical criteria for PCA, in that his presenting difficulty was the insidious onset of a primary visual dysfunction (Tang-Wai *et al.*, 2004). It is not uncommon that the first visual dysfunction in PCA is progressive peripheral alexia (Benson *et al.*, 1988; McMonagle *et al.*, 2006; Mendez *et al.*, 2007). Patient J did not have any other significant visual or visuospatial deficits, although he made some errors on the number location subtest from the Visual Object and Space Perception battery, which may be a harbinger of the emergence of a more generalized visual impairment.

Some authors have proposed that distinct variants of PCA differentially involve dorsal and ventral visual streams (Caselli, 1995; Mackenzie Ross *et al.*, 1996; Beversdorf and Heilman, 1998; Mendez and Chierri, 1998; Migliaccio *et al.*, 2012) or that there is a continuum between dorsal and ventral forms (Lehmann *et al.*, 2011), whereas others have argued that the dorsal stream is generally more affected than the ventral stream (McMonagle *et al.*, 2006). Mendez and Chierri (1998) reported two cases of PCA in which alexia with letter-by-letter reading was the first symptom, but both patients eventually developed a more general ventral simultanagnosia and eventually dorsal simultanagnosia. In contrast, Mendez (2001) reported another patient with PCA with deficits primarily affecting visual localization and visuospatial integration, in whom reading was largely preserved. PET showed bilateral occipito-parietal hypometabolism. In another patient with occipito-parietal degeneration, Vinckier *et al.* (2006) showed that reading was preserved, except in situations that make particular demands on visuospatial processing, such as

rotated words, or words with spaces between the letters. Taken together, these cases suggest that peripheral alexia with letter-by-letter reading in PCA is related to dysfunction of ventral rather than dorsal visual regions (Mendez and Cherrier, 1998; Mendez, 2001).

Our findings with Patient J are consistent with this view. The functional abnormalities we observed were ventral, as was the mild structural atrophy, consistent with progressive alexia being the only prominent symptom in this case. We concur with previous researchers that there are multiple variants of PCA depending on the particular regions affected (Caselli, 1995; Mackenzie Ross *et al.*, 1996; Lehmann *et al.*, 2011; Migliaccio *et al.*, 2012), and that cases in which alexia is the first and most prominent symptom reflect a ventral variant (Beversdorf and Heilman, 1998; Mendez and Cherrier, 1998).

Patient B met clinical criteria for logopenic primary progressive aphasia. He showed progressive alexia with a prominent peripheral component, as evidenced by letter-by-letter reading, as well as a central spelling deficit, and significant aphasia. Although logopenic primary progressive aphasia is associated with reading deficits (Brambati *et al.*, 2009; Henry *et al.*, 2012), such deficits are typically central in nature; to our knowledge, no previous cases have been reported with significant peripheral deficits as well. Patient B's unique pattern of impairment can be explained in terms of his atrophy, which encompassed both posterior perisylvian cortex, accounting for spoken language deficits and possibly contributing to his spelling impairment, as well as occipito-temporal regions, accounting for peripheral alexia. Patient B's atrophy was also strongly left-lateralized, which is consistent with his relatively spared visuo-spatial functions. It has been suggested that PCA and logopenic primary progressive aphasia have much in common as atypical Alzheimer's variants, and may differ primarily in relative lateralization of posterior atrophy (Migliaccio *et al.*, 2009).

In conclusion, we have shown that the visual word form system was functionally abnormal in two cases of progressive alexia, despite the fact that the VWFA was neither completely destroyed nor were there any frank lesions that would disconnect it from its afferents. This functional abnormality was accompanied by substantial atrophy in only one of the two cases, indicating that defective activation of the visual word form system resulting in profound alexia may precede significant atrophy.

Acknowledgements

We thank Scott Squire, Sarah Andersen, Ashley Chavez and Adam Gendreau for assistance with functional imaging data collection, Kate Possin for help with visuospatial assessments, Cyma Van Petten, Elena Plante and Dianne Patterson for sharing control structural data, three anonymous reviewers for their constructive comments, and the individuals who participated in our study, especially Patient J and Patient B for their time and patience.

Funding

This work was supported by the National Institutes of Health [DC010878 to S.M.W., DC007646 to P.B., DC008286 to S.Z.R.

and P.B., AG014792 to Cyma Van Petten] and the University of Arizona.

Supplementary material

Supplementary material is available at *Brain* online.

References

- Ardila A, Rosselli M, Arvizu L, Kuljis RO. Alexia and agraphia in posterior cortical atrophy. *Neuropsychiatry Neuropsychol Behav Neurol* 1997; 10: 52–9.
- Ashburner J, Friston KJ. Unified segmentation. *Neuroimage* 2005; 26: 839–51.
- Beeson PM, Rising K, Kim ES, Rapcsak SZ. A treatment sequence for phonological alexia/agraphia. *J. Speech Lang Hear Res* 2010; 53: 450–68.
- Behrmann M, Plaut DC, Nelson J. A literature review and new data supporting an interactive account of letter-by-letter reading. *Cogn Neuropsychol* 1998; 15: 7–51.
- Benson DF, Davis RJ, Snyder BD. Posterior cortical atrophy. *Arch Neurol* 1988; 45: 789–93.
- Beversdorf DQ, Heilman KM. Progressive ventral posterior cortical degeneration presenting as alexia for music and words. *Neurology* 1998; 50: 657–9.
- Beversdorf DQ, Ratcliffe NR, Rhodes CH, Reeves AG. Pure alexia: clinical-pathologic evidence for a lateralized visual language association cortex. *Clin Neuropathol* 1997; 16: 328–31.
- Binder JR, Mohr JP. The topography of callosal reading pathways. A case-control analysis. *Brain* 1992; 115: 1807–26.
- Brainard DH. The psychophysics toolbox. *Spat Vis* 1997; 10: 433–6.
- Brambati SM, Ogar J, Neuhaus J, Miller BL, Gorno-Tempini ML. Reading disorders in primary progressive aphasia: a behavioral and neuroimaging study. *Neuropsychologia* 2009; 47: 1893–1900.
- Caselli RJ. Focal and asymmetric cortical degeneration syndromes. *Neurologist* 1995; 1: 1–19.
- Catricalà E, Rosa PAD, Ortellì P, Ginex V, Marcone A, Perani D, *et al.* The evolution of alexia in two cases of posterior cortical atrophy. *Behav Neurol* 2011; 24: 229–36.
- Clarke S. The role of homotopic and heterotopic callosal connections in humans. In: Zaidel E, Iacoboni M, editors. *The Parallel Brain*. Cambridge, MA: MIT Press; 2003. p. 461–72.
- Cogan DG. Visual disturbances with focal progressive dementing disease. *Am J Ophthalmol* 1985; 100: 68–72.
- Cohen L, Dehaene S, Naccache L, Lehéricy S, Dehaene-Lambertz G, Hénaff MA, *et al.* The visual word form area: spatial and temporal characterization of an initial stage of reading in normal subjects and posterior split-brain patients. *Brain* 2000; 123: 291–307.
- Cohen L, Henry C, Dehaene S, Martinaud O, Lehéricy S, Lemer C, *et al.* The pathophysiology of letter-by-letter reading. *Neuropsychologia* 2004; 42: 1768–80.
- Cohen L, Lehéricy S, Chochon F, Lemer C, Rivaud S, Dehaene S. Language-specific tuning of visual cortex? Functional properties of the Visual Word Form Area. *Brain* 2002; 125: 1054–69.
- Cohen L, Martinaud O, Lemer C, Lehéricy S, Samson Y, Obadia M, *et al.* Visual word recognition in the left and right hemispheres: anatomical and functional correlates of peripheral alexias. *Cereb Cortex* 2003; 13: 1313–33.
- Coltheart M. The MRC psycholinguistic database. *Q J Exp Psychol A* 1981; 33A: 497–505.
- Cox RW. AFNI: software for analysis and visualization of functional magnetic resonance neuroimages. *Comput Biomed Res* 1996; 29: 162–173.
- Crutch SJ, Warrington EK. Foveal crowding in posterior cortical atrophy: a specific early-visual-processing deficit affecting word reading. *Cogn Neuropsychol* 2007; 24: 843–66.

- Crutch SJ, Warrington EK. The relationship between visual crowding and letter confusability: towards an understanding of dyslexia in posterior cortical atrophy. *Cogn Neuropsychol* 2009; 26: 471–98.
- Damasio AR, Damasio H. The anatomic basis of pure alexia. *Neurology* 1983; 33: 1573–83.
- De Renzi E. Slowly progressive visual agnosia or apraxia without dementia. *Cortex* 1986; 22: 171–80.
- Dehaene S, Cohen L. The unique role of the visual word form area in reading. *Trends Cogn Sci* 2011; 15: 254–62.
- Dehaene S, Cohen L, Sigman M, Vinckier F. The neural code for written words: a proposal. *Trends Cogn* 2005; 9: 335–41.
- Dejerine J. Contribution à l'étude anatomo-pathologique et clinique des différentes variétés de cécité-verbale. *Mémoires Société Biologique* 1892; 4: 61–90.
- Epelbaum S, Pinel P, Gaillard R, Delmaire C, Perrin M, Dupont S, et al. Pure alexia as a disconnection syndrome: new diffusion imaging evidence for an old concept. *Cortex* 2008; 44: 962–74.
- Folstein MF, Folstein SE, McHugh PR. 'Mini-mental state': A practical method for grading the cognitive state of patients for the clinician. *J Psychiatr Res* 1975; 12: 189–98.
- Fragassi NA, Chiacchio L, Errichiello L, Pappatà S, Tedeschi MR, Striano P, et al. Posterior cortical atrophy with prominent alexia without agraphia in a Tourette syndrome. *Neurol Sci* 2011; 32: 1129–33.
- Freedman L, Costa L. Pure alexia and right hemiachromatopsia in posterior dementia. *J Neurol Neurosurg Psychiatr* 1992; 55: 500–2.
- Freedman L, Selchen DH, Black SE, Kaplan R, Garnett ES, Nahmias C. Posterior cortical dementia with alexia: neurobehavioural, MRI, and PET findings. *J Neurol Neurosurg Psychiatr* 1991; 54: 443–8.
- Friston KJ. Testing for anatomically specified regional effects. *Hum Brain Mapp* 1997; 5: 133–136.
- Froming K, Levy M, Schaffer S, Ekman P. The comprehensive affect testing system. psychology software, Inc 2006.
- Gaillard R, Naccache L, Pinel P, Clémenceau S, Volle E, Hasboun D, et al. Direct intracranial, fMRI, and lesion evidence for the causal role of left inferotemporal cortex in reading. *Neuron* 2006; 50: 191–204.
- Giovagnoli AR, Aresi A, Reati F, Riva A, Gobbo C, Bizzi A. The neuropsychological and neuroradiological correlates of slowly progressive visual agnosia. *Neurol Sci* 2009; 30: 123–31.
- Glezer LS, Jiang X, Riesenhuber M. Evidence for highly selective neuronal tuning to whole words in the 'visual word form area'. *Neuron* 2009; 62: 199–204.
- Glover GH, Law CS. Spiral-in/out BOLD fMRI for increased SNR and reduced susceptibility artifacts. *Magn Reson Med* 2001; 46: 515–22.
- Gorno-Tempini M L, Hillis AE, Weintraub S, Kertesz A, Mendez M, Cappa SF, et al. Classification of primary progressive aphasia and its variants. *Neurology* 2011; 76: 1006–14.
- Graff-Radford NR, Bolling JP, Earnest F 4th, Shuster EA, Caselli RJ, Brazis PW. Simultanagnosia as the initial sign of degenerative dementia. *Mayo Clin Proc* 1993; 68: 955–64.
- Grainger J, Whitney C. Does the human mind read words as a whole? *Trends Cogn Sci* 2004; 8: 58–9.
- Henry C, Gaillard Raphaël, Volle E, Chiras J, Ferrieux S, Dehaene Stanislas, et al. Brain activations during letter-by-letter reading: a follow-up study. *Neuropsychologia* 2005; 43: 1983–1989.
- Henry ML, Beeson PM, Alexander GE, Rapcsak SZ. Written language impairments in primary progressive aphasia: a reflection of damage to central semantic and phonological processes. *J Cogn Neurosci* 2012; 24: 261–75.
- Henry ML, Beeson PM, Stark AJ, Rapcsak SZ. The role of left perisylvian cortical regions in spelling. *Brain Lang* 2007; 100: 44–52.
- Hodges JR, Patterson K, Oxbury S, Funnell E. Semantic dementia. Progressive fluent aphasia with temporal lobe atrophy. *Brain* 1992; 115: 1783–806.
- Hof PR, Vogt BA, Bouras C, Morrison JH. Atypical form of Alzheimer's disease with prominent posterior cortical atrophy: a review of lesion distribution and circuit disconnection in cortical visual pathways. *Vision Res* 1997; 37: 3609–25.
- Ino T, Tokumoto K, Usami K, Kimura T, Hashimoto Y, Fukuyama H. Longitudinal fMRI study of reading in a patient with letter-by-letter reading. *Cortex* 2008; 44: 773–81.
- Jefferies E, Lambon Ralph MA, Jones R, Bateman D, Patterson K. Surface dyslexia in semantic dementia: a comparison of the influence of consistency and regularity. *Neurocase* 2004; 10: 290–9.
- Kaplan EF, Goodglass H, Weintraub S. The Boston naming test. 2nd edn. Philadelphia: Lea and Febiger; 1983.
- Kay J, Lesser R, Coltheart M. PALPA: Psycholinguistic assessments of language processing in aphasia. Hove: Lawrence Erlbaum Associates; 1992.
- Kertesz A. Western aphasia battery. New York: Grune and Stratton; 1982.
- Leff AP, Spitsyna G, Plant GT, Wise RJS. Structural anatomy of pure and hemianopic alexia. *J Neurol Neurosurg Psychiatr* 2006; 77: 1004–7.
- Lehmann M, Barnes J, Ridgway GR, Wattam-Bell J, Warrington Elizabeth K, Fox NC, et al. Basic visual function and cortical thickness patterns in posterior cortical atrophy. *Cereb Cortex* 2011; 21: 2122–32.
- Mackenzie Ross SJ, Graham N, Stuart-Green L, Prins M, Xuereb J, Patterson K, et al. Progressive biparietal atrophy: an atypical presentation of Alzheimer's disease. *J Neurol Neurosurg Psychiatr* 1996; 61: 388–95.
- Mani J, Diehl B, Piao Z, Schuele SS, Lapresto E, Liu P, et al. Evidence for a basal temporal visual language center: cortical stimulation producing pure alexia. *Neurology* 2008; 71: 1621–7.
- McCrory EJ, Mechelli A, Frith U, Price CJ. More than words: a common neural basis for reading and naming deficits in developmental dyslexia? *Brain* 2005; 128: 261–7.
- McMonagle P, Deering F, Berliner Y, Kertesz A. The cognitive profile of posterior cortical atrophy. *Neurology* 2006; 66: 331–8.
- Mendez MF. Visuospatial deficits with preserved reading ability in a patient with posterior cortical atrophy. *Cortex* 2001; 37: 535–43.
- Mendez MF. Slowly progressive alexia. *J Neuropsychiatry Clin Neurosci* 2002; 14: 84.
- Mendez MF, Chierri MM. The evolution of alexia and simultanagnosia in posterior cortical atrophy. *Neuropsychiatry Neuropsychol Behav Neurol* 1998; 11: 76–82.
- Mendez MF, Ghajarania M, Perryman KM. Posterior cortical atrophy: clinical characteristics and differences compared to Alzheimer's disease. *Dement Geriatr Cogn Disord* 2002; 14: 33–40.
- Mendez MF, Shapira JS, Clark DG. 'Apperceptive' alexia in posterior cortical atrophy. *Cortex* 2007; 43: 264–70.
- Migliaccio R, Agosta F, Rascovsky K, Karydas A, Bonasera S, Rabinovici GD, et al. Clinical syndromes associated with posterior atrophy: early age at onset AD spectrum. *Neurology* 2009; 73: 1571–8.
- Migliaccio R, Agosta F, Scola E, Magnani G, Cappa SF, Pagani E, et al. Ventral and dorsal visual streams in posterior cortical atrophy: A DT MRI. *Neurobiol Aging* 2012; 33: 2572–84.
- Molko N, Cohen L, Mangin JF, Chochon F, Lehericy S, Le Bihan D, et al. Visualizing the neural bases of a disconnection syndrome with diffusion tensor imaging. *J Cogn Neurosci* 2002; 14: 629–36.
- Noble K, Glosser G, Grossman M. Oral reading in dementia. *Brain Lang* 2000; 74: 48–69.
- Patterson K, Hodges JR. Deterioration of word meaning: implications for reading. *Neuropsychologia* 1992; 30: 1025–40.
- Pelli DG. The VideoToolbox software for visual psychophysics: transforming numbers into movies. *Spat Vis* 1997; 10: 437–42.
- Pflugshaupt T, Gutbrod K, Wurtz P, von Wartburg R, Nyffeler T, de Haan B, et al. About the role of visual field defects in pure alexia. *Brain* 2009; 132: 1907–17.
- Possin KL, Laluz VR, Alcantar OZ, Miller BL, Kramer JH. Distinct neuro-anatomical substrates and cognitive mechanisms of figure copy performance in Alzheimer's disease and behavioral variant frontotemporal dementia. *Neuropsychologia* 2011; 49: 43–8.
- Price CJ, Devlin JT. The myth of the visual word form area. *Neuroimage* 2003; 19: 473–81.

- Price CJ, Devlin JT. The interactive account of ventral occipitotemporal contributions to reading. *Trends Cogn Sci* 2011; 15: 246–53.
- Rapcsak SZ, Beeson PM. The role of left posterior inferior temporal cortex in spelling. *Neurology* 2004; 62: 2221–9.
- Rapcsak SZ, Beeson PM, Henry ML, Leyden A, Kim E, Rising K, et al. Phonological dyslexia and dysgraphia: cognitive mechanisms and neural substrates. *Cortex* 2009; 45: 575–91.
- Raven JC, Court JH, Raven J. Coloured progressive matrices. Oxford: Oxford Psychologists Press; 1990.
- Rumsey JM, Nace K, Donohue B, Wise D, Maisog JM, Andreason P. A positron emission tomographic study of impaired word recognition and phonological processing in dyslexic men. *Arch Neurol* 1997; 54: 562–73.
- Salmelin R, Service E, Kiesilä P, Uutela K, Salonen O. Impaired visual word processing in dyslexia revealed with magnetoencephalography. *Ann Neurol* 1996; 40: 157–62.
- Snowden JS, Kindell J, Thompson JC, Richardson AMT, Neary D. Progressive aphasia presenting with deep dyslexia and dysgraphia. *Cortex* 2012; 48: 1234–9.
- Tagamets MA, Novick JM, Chalmers ML, Friedman RB. A parametric approach to orthographic processing in the brain: an fMRI study. *J Cogn Neurosci* 2000; 12: 281–97.
- Tang-Wai DF, Graff-Radford NR, Boeve BF, Dickson DW, Parisi JE, Crook R, et al. Clinical, genetic, and neuropathologic characteristics of posterior cortical atrophy. *Neurology* 2004; 63: 1168–74.
- Tombaugh TN. Trail Making Test A and B: normative data stratified by age and education. *Arch Clin Neuropsychol* 2004; 19: 203–214.
- Tsapkini K, Rapp B. The orthography-specific functions of the left fusiform gyrus: evidence of modality and category specificity. *Cortex* 2010; 46: 185–205.
- Tsapkini K, Vindiola M, Rapp B. Patterns of brain reorganization subsequent to left fusiform damage: fMRI evidence from visual processing of words and pseudowords, faces and objects. *Neuroimage* 2011; 55: 1357–72.
- Van der Haegen L, Cai Q, Brysbaert M. Colateralization of Broca's area and the visual word form area in left-handers: fMRI evidence. *Brain Lang* 2012; 122: 171–178.
- van der Mark S, Bucher K, Maurer U, Schulz E, Brem S, Buckelmüller J, et al. Children with dyslexia lack multiple specializations along the visual word-form (VWF) system. *Neuroimage* 2009; 47: 1940–9.
- van der Mark S, Klaver P, Bucher K, Maurer U, Schulz E, Brem S, et al. The left occipitotemporal system in reading: disruption of focal fMRI connectivity to left inferior frontal and inferior parietal language areas in children with dyslexia. *Neuroimage* 2011; 54: 2426–36.
- Victoroff J, Ross GW, Benson DF, Verity MA, Vinters HV. Posterior cortical atrophy. Neuropathologic correlations. *Arch Neurol* 1994; 51: 269–74.
- Vinckier F, Dehaene S, Jobert A, Dubus JP, Sigman M, Cohen L. Hierarchical coding of letter strings in the ventral stream: dissecting the inner organization of the visual word-form system. *Neuron* 2007; 55: 143–56.
- Vinckier F, Naccache L, Papeix C, Forget J, Hahn-Barma V, Dehaene S, et al. 'What' and 'where' in word reading: ventral coding of written words revealed by parietal atrophy. *J Cogn Neurosci* 2006; 18: 1998–2012.
- Vogel AC, Petersen SE, Schlaggar BL. The left occipitotemporal cortex does not show preferential activity for words. *Cereb Cortex* 2012; 22: 2715–32.
- Warrington E K, James M. Visual Object and Space Perception Battery. Bury St Edmunds: Thames Valley; 1991.
- Warrington EK, Shallice T. Word-form dyslexia. *Brain* 1980; 103: 99–112.
- Whitwell JL, Jack CR Jr, Kantarci K, Weigand SD, Boeve BF, Knopman DS, et al. Imaging correlates of posterior cortical atrophy. *Neurobiol Aging* 2007; 28: 1051–61.
- Wilson SM, Brambati SM, Henry RG, Handwerker DA, Agosta F, Miller BL, et al. The neural basis of surface dyslexia in semantic dementia. *Brain* 2009; 132: 71–86.
- Wilson SM, Henry ML, Besbris M, Ogar JM, Dronkers NF, Jarrold W, et al. Connected speech production in three variants of primary progressive aphasia. *Brain* 2010; 133: 2069–88.
- Worsley KJ, Liao CH, Aston J, Petre V, Duncan GH, Morales F, et al. A general statistical analysis for fMRI data. *Neuroimage* 2002; 15: 1–15.
- Worsley KJ, Marrett S, Neelin P, Vandal AC, Friston KJ, Evans AC, et al. A unified statistical approach for determining significant signals in images of cerebral activation. *Hum Brain Mapp* 1996; 4: 58–73.